



## Clinical effectiveness of non-invasive selective cryolipolysis

JIEHOON KIM<sup>1</sup>, DAI HYUN KIM<sup>2</sup> & HWA JUNG RYU<sup>2</sup>

<sup>1</sup>Dr. Kim's Skin & Laser Clinic, Dermatology, Suwon, Republic of Korea and <sup>2</sup>Department of Dermatology, Korea University College of Medicine, Seoul, Republic of Korea

### Abstract

**Background:** Excess subcutaneous fat causes not only cosmetic issues, but also substantial systemic health problems. Cryolipolysis has been reported to provide non-invasive fat reduction that significantly reduces subcutaneous fat cells with controlled, localized cooling. **Objective:** This study is intended to determine whether a cryolipolysis device can effectively reduce subcutaneous fat without damaging the overlying skin or causing significant side effects and ultimately produce improved cosmetic results. **Materials and methods:** A total of 15 patients participated in this study and they were treated unilaterally in a split-body trial manner with a non-invasive cryolipolysis device (Micool™, Hironic Co., Seongnam, Korea). The degree of improvement was assessed by both objective and subjective assessments. Complications and side effects were recorded at every visit. **Results:** The results of both objective and subjective assessments showed significant improvements in subcutaneous fat reduction without any meaningful complications. **Conclusion:** Non-invasive selective cryolipolysis has been reported to be a safe and effective treatment modality for the reduction of excess adipose tissue. Therefore, cryolipolysis is a promising technology that could be an appropriate and safe therapeutic option for subcutaneous fat reduction.

**Key Words:** fat removal, cryolipolysis

### Introduction

Unwanted excess subcutaneous fat negatively impacts not only body shape and image, but also causes various chronic diseases. Therefore, concerns of the public, physicians, and scientists have been growing, and the media has been promoting the image of a slim body as the virtue of beauty and health.

Among the numerous therapeutic modalities that have been developed so far, liposuction still remains the most common surgical cosmetic procedure. Although liposuction is an effective therapeutic option for the removal of fat and can be safely performed as an outpatient procedure, it is an invasive method with surgical risks, such as infection, scarring, hematoma, deep vein thrombosis, and pulmonary embolism, in addition to the specific risks associated with general anesthesia (1,2).

A non-invasive procedure that also enables effective fat removal is necessary because of the potential side effects of liposuction. Many such non-invasive treatment methods have been developed, including

endermologie (LPG Systems, Valence, France), radiofrequency treatment, and light-based treatment (lasers or low level light therapy) (3–5). However, the therapeutic results of these methods are not as satisfactory and they are therefore used as adjunct methods to liposuction. High intensity focused ultrasound (HIFU) is regarded as a treatment that safely and effectively reduces subcutaneous fat tissues (6); however, it is still difficult to use widely because of the pain and high cost of consumable devices.

Non-invasive selective cryolipolysis is a new technology that uses cold exposure or energy extraction to cause localized panniculitis and fat modulation. This technology is based on clinical observations that cold exposure, under the proper circumstances, can result in localized panniculitis. This panniculitis ultimately results in the reduction and clearance of adipose tissue without injury to the surrounding normal tissue (7). Micool™ (Hironic Co., Seongnam, Korea) is a non-invasive selective cryolipolysis device and

was approved by the Ministry of Food and Drug Safety (MFDS) of the Korean government in 2013. Several articles have been published reporting the efficacy of non-invasive devices (Zeltiq Aesthetics, Pleasanton, CA), but nothing has been documented related to Micool™, despite its growing clinical usage in Korea. This study aimed to determine the effectiveness of the Micool™ cryolipolysis device and ensure that it does not damage the overlying skin or cause significant side effects.

### Material and methods

The subjects in this study were patients who visited Dr. Kim's Skin & Laser Clinic from April to November, 2013. Eligible subjects were men and women who were older than 20 years of age with more than a moderate degree of obesity. Potential subjects were excluded if they had received liposuction or another surgical procedure in the intended treatment area; had a history of subcutaneous injections into the area within the past 4 weeks; had a history of chronic disease such as hypertension, diabetes, or hyperlipidemia; had a significant psychiatric problem such as body dysmorphism; or had taken diet pills within the past 4 weeks. Individuals who were pregnant or lactating were also excluded from the study.

Potential side effects were fully explained to the patients prior to treatment and these included erythema, bruising, and neurologic complications such as tenderness, dulling of sensation or numbness, and tingling. These expected complications and other possibly related findings were documented directly after treatment as well as 3 months after each procedure. They all agreed to the use of their photos and informed consent was obtained from all of the patients.

The targeted treatment sites were visible fat on the flanks ('love handles'), lower abdomen (belly), upper chest (bra-line), upper hip, under the buttocks, or inner thigh (Figure 1B). In principle, the cryolipolysis device was eventually applied to both sides of the targeted area; however, sequential split-body trials were done for more accurate comparison of clinical efficacy. In detail, individuals received treatment on one side and the following procedure was completed after 3 months of close observation.

Each patient met with the medical assistant for baseline photographs, after which the physician performed cryolipolysis. Digital photographic images were documented under controlled conditions with the same light source, room, and camera before the treatment and during each session. The patients were treated with a non-invasive selective cryolipolysis device using a cooling intensity factor (CIF) of 33 ( $-64 \text{ mW/cm}^2$ ) for 60 minutes per application site. CIF is the index representing the rate of heat flux into or out of the tissue opposite the cooling device.

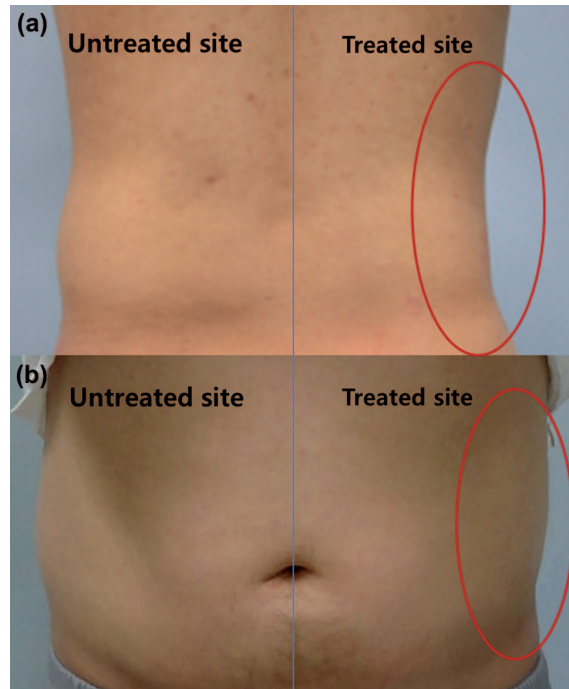


Figure 1. Clinical photographs of the split-body trial case. A 41-year-old male patient showed excellent response on his right love handle area (a), and a 36-year-old male patient also had a significantly satisfactory result on his left love handle site (b) 3 months after the cryolipolysis procedure.

In this study, all subjects were requested to revisit the clinic for clinical photographs and assessment 2 weeks, 1 month, 2 months, and 3 months after each procedure. The results of the cryolipolysis treatment were analyzed using both subjective evaluations by the patients and objective assessments by the physicians. Objective improvement was assessed with clinical photography after the final session and 3 months thereafter on a 5-point scale as follows: 1 = excellent improvement or  $>75\%$  subcutaneous fat reduction, 2 = good improvement or  $50\text{--}75\%$  subcutaneous fat reduction, 3 = fair improvement or  $25\text{--}50\%$  subcutaneous fat reduction, 4 = noticeable improvement or  $10\text{--}25\%$  subcutaneous fat reduction, 5 = no improvement or  $0\text{--}10\%$  subcutaneous fat reduction. The data collected at baseline and 3 months post-treatment were compared for a final estimation of the clinical value. The objective assessment was performed by two independent and experienced dermatologists. The subjective assessment was obtained with a questionnaire composed of a 5-point scale as follows: 1 = significantly satisfactory, 2 = moderately satisfactory, 3 = slightly satisfactory, 4 = moderately unsatisfactory, and 5 = significantly unsatisfactory.

Statistical analysis was performed using SPSS version 19.0 for Windows (Statistical Package for the Social Sciences, SPSS, Chicago, USA). The paired

t-test was used for evaluation of statistical significance between the scores of both objective and subjective assessments at baseline and 3 months after treatment. Differences were considered statistically significant when  $p < 0.05$ .

## Results

Initially, 18 patients volunteered to participate in the study; however, 3 patients were conclusively excluded from the study due to loss to follow-up. The reason for loss to follow-up was not related to results of the procedure, such as unsatisfactory outcomes or complications, and was due to personal affairs. A total of 15 patients (11 women and 4 men) fulfilled all of the requirements of the investigation. The mean age was 30.1 years, with a range of 22 to 41. Treatments were delivered primarily to the love handles (40.0%,  $n = 6$ ), belly (20.0%,  $n = 3$ ), upper hip (13.3%,  $n = 2$ ), inner thigh (13.3%,  $n = 2$ ), bra line (6.7%,  $n = 1$ ), and under the buttocks (6.7%,  $n = 1$ ). Patient information and assessment outcomes are described in Table I.

The treatments delivered to different anatomic sites were also analyzed by gender. Men almost exclusively received treatment to the love handles (50.0%,  $n = 2$ ) and belly (50.0%,  $n = 2$ ). Women, in comparison, received treatment over a much wider range of areas, including the love handles (36.4%,  $n = 4$ ), upper hip (18.2%,  $n = 2$ ), inner thigh (18.2%,  $n = 2$ ), bra line (9.1%,  $n = 1$ ), belly (9.1%,  $n = 1$ ), and under the buttocks (9.1%,  $n = 1$ ). The treatment sites were also analyzed by patient age range. The patients were divided into 2 groups, 20 to 29 years old and more than 30 years old. The number of patients in each group was similar, with 8 for the former and 7 for the latter; however, the composition was quite different. The treatment sites of the former group were love handles (37.5%,  $n = 3$ ), upper hip (25.0%,

$n = 2$ ), inner thigh (25.0%,  $n = 2$ ), and banana muffin (12.5%,  $n = 1$ ). The latter group received treatments of the love handles (42.9%,  $n = 3$ ), belly (42.9%,  $n = 3$ ), and bra line (14.3%,  $n = 1$ ). It can be assumed that both groups were interested in treatment of the love handles, but the younger group desired modification of the thigh or hip area and the older group was more concerned with their belly.

Results of both the objective and subjective assessments were revealed to be statistically significant ( $p < 0.05$ ) compared to the baseline state. The average point of the objective assessment was 1.7, which implies good to excellent improvement or 50% to 100% subcutaneous fat reduction. The average of the subjective assessment was 2.1, indicating moderately satisfactory results. The assessments were also analyzed by gender and treatment site. The average values of the objective and subjective assessments of male patients were 1.5 and 1.8, respectively. The average points for female subjects were 1.8 and 2.2, respectively. It seemed that the male patients showed slightly more favorable results with cryolipolysis than their female counterparts. The most satisfactory treatment site was area under the buttocks, followed by the love handle. The average values for the objective and subjective assessments of under the buttocks were 1.0 and 1.0, and the love handle showed points of 1.3 and 1.5, respectively. Clinical photos of love handle treatment by cryolipolysis are described in Figure 1. The male patients received cryolipolysis treatment once on the right and once on the left love handle area. After 3 months, they all showed excellent improvement and expressed significant satisfaction with the results. The most dissatisfactory area was the bra line followed by the inner thigh. The average values for both the objective and subjective assessments of the bra line were 3.0 and 4.0, respectively, and the values for the inner thigh were 2.0 and 3.0, respectively.

Each subject was closely observed and managed for possible complications during the entire course of the study. All patients experienced immediate erythema (Figure 2a) and minor pain for several hours, but these symptoms vanished within one day without specific management. Bruising (Figure 2b) emerged in some patients at the treatment site and disappeared within 2 to 5 days without further treatment. Neurologic complications, such as tenderness, dulling of sensation or numbness, or tingling sensation, were not reported until 3 months after the last procedure. All patients were also shown to have no other long-lasting symptoms or discomfort at the last questionnaire 3 months after the last treatment.

## Discussion

Cryolipolysis is a new method to use controlled fat cooling, also known as energy extraction, to cause

Table I. Patient demographics and the results of both objective and subjective assessments.

Patient number	Gender/ Age	Location	Objective assessment	Subjective assessment
1	F/27	Love handle	2	2
2	F/22	Thigh	2	3
3	M/37	Belly	2	2
4	F/22	Upper hip	2	2
5	M/35	Belly	2	3
6	F/23	Under the buttocks	1	1
7	F/25	Love handle	1	1
8	F/38	Belly	2	2
9	F/27	Love handle	1	2
10	M/41	Love handle	1	1
11	F/38	Bra line	3	4
12	F/25	Inner thigh	2	3
13	F/30	Love handle	2	2
14	F/26	Upper hip	2	2
15	M/36	Love handle	1	1

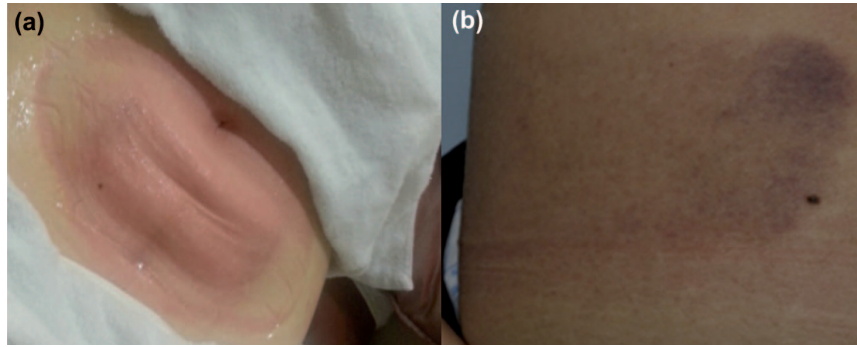


Figure 2. The most common side effects related to cryolipolysis: erythema (a) and bruising (b). The majority of the erythema events lasted for several hours and vanished within 1 day without specific management. The bruising also disappeared within 2 to 5 days without further treatment. There was no reported long lasting or permanent complication among the subjects.

localized panniculitis that finally result in fat reduction. In detail, exposure to cold can cause localized inflammation of the subcutaneous fat layer, known as cold panniculitis (8). Manstein et al. expanded on this idea and conducted animal studies to determine if controlled, localized exposure of the skin to cold could result in selective destruction of subcutaneous fat cells. Additional porcine studies led by Zelickson et al. supported the theory that cryolipolysis could selectively reduce adipocytes without injury to the surrounding tissues (9). Therefore, by controlling and modulating the cold exposure, it could be possible to selectively damage human adipocytes while avoiding damage to the overlying epidermis and dermis. This would result in an effective, localized, and non-invasive treatment for excess adipose tissue.

A new method of non-invasive fat layer reduction called selective cryolipolysis has been recently reported to show significant reduction of subcutaneous fat layer thickness. A cold-induced inflammatory mechanism gradually reduces fat thickness in 90 days after a 30- to 60-min cold plate exposure to the skin surface (10,11). The current understanding of this mechanism is that cold exposure results in inflammation, damage to fat cells, and ultimately induces subsequent loss of subcutaneous adipocytes. It is hypothesized that adipocyte apoptosis stimulates the initial inflammatory infiltrate. After cryolipolysis treatment, the infiltrate becomes denser and an intense lobular panniculitis develops within a week. Between 14 and 30 days following treatment, the inflammatory infiltrate becomes increasingly monocytic, which is consistent with a phagocytic process. Macrophages digest the apoptotic adipocytes, thereby facilitating their elimination from the body. As this process occurs, the average size of the adipocytes decrease, a wider range of adipocyte sizes are observed, and the fibrous septa of the fat layer widen. The actual elimination of the adipocytes from the body occurs slowly over at least the next 90 days. The exact mechanism and pathway by which the

phagocytized adipocytes are eliminated from the body are not fully understood at present. Clinically, this corresponds to a decrease in the thickness of the subcutaneous fat layer (7,9). The initial animal studies have helped to shape the likely mechanism of cryolipolysis; however, it should be stressed that the exact mechanism has not been completely explained. As the technology continues to be developed, future studies will need to further investigate these issues.

Non-invasive selective cryolipolysis is a relatively new therapeutic modality in the field of liporeduction and has many advantages for clinical use, such as safety, tolerability, and the capability to reduce the thickness of the subcutaneous fat layer without damage to the overlying skin or associated structures. Several articles have reported that cryolipolysis itself could effectively manage excess adipose tissue on the love handles, belly, bra-line, upper hip, under the buttocks, and inner thigh (10,12). The result of our study also showed a similar outcome compared to former studies, except a few findings such as more favorable results in men and treatment site superiorities for the love handles and the area under the buttocks. Other therapeutic modalities often require combined treatment with diet therapy, endermologie, or radiofrequency. Unlike these other treatment methods using destruction or necrosis of adipocytes and subsequent absorption, cryolipolysis induces natural cellular apoptosis and therefore, cryolipolysis could be capable of physiologic and gradual removal of excess adipocytes (13).

Furthermore, non-invasive selective cryolipolysis is comparably more convenient because there is no need to cautiously inject specific materials and continuously move the handpiece. Cryolipolysis only requires attachment of the applicator to a targeted site and observation for 30 to 60 minutes. Unlike liposuction, general anesthesia is not necessary and therefore, there was no requirement for further medical staff or related complex facilities. The patient can express symptoms or complain about specific discomfort in their awakened status. For that reason,

the risks of the procedure can be significantly lowered. In addition, the non-invasive selective cryolipolysis device has a short learning curve due to its simple interface, which is easy to manipulate. Therefore, it is relatively independent of the experience of the physician.

Non-invasive selective cryolipolysis has other strengths in the aspect of safety. Patients typically develop erythema at the treatment area where the applicators are attached, which can last up to a few hours following cryolipolysis (Figure 2a). Because the device uses a vacuum to increase clinical efficacy, patients may also develop bruises at the treatment sites (Figure 2b), which may disappear within 1 week without specific management. The treated skin can also become cold and firm following cryolipolysis treatment. In all clinical studies to date, no ulceration or scarring has been reported, including in our experience. Theoretically, the process of adipocyte apoptosis and clearing of the liberated lipid could result in elevation of serum lipids. However, animal studies of cryolipolysis have shown that after treatment of a large surface area, which resulted in a 30–50% reduction in fat layer thickness, serum lipid levels remained within normal limits over the subsequent 3 months (7,9). Human studies have also reported that no significant changes in mean values were observed for any blood lipid level or liver test at any point over the 12-week follow-up period (14). Cryolipolysis has become known by human subjects to result in a temporary dulling of sensation and numbness in the treated areas. Cryolipolysis results in a decrease in sensation of treated areas, but this altered sensation is transient and appears to resolve shortly after treatment without any further intervention. In summary, cold exposure to achieve significant cryolipolysis is not associated with significant nerve injury (15). In our experience, almost all of the complications related to cryolipolysis were transient and vanished in a short time without further care, and even if the symptoms lasted for an unusually long time or were severe, these could be sufficiently managed by warm compresses or anti-inflammatory agents.

In conclusion, non-invasive selective cryolipolysis appears to be a safe and effective treatment option for the reduction of excess adipose tissue. Although the exact pathophysiology of cryolipolysis should be verified by further research, cryolipolysis is still a promising technology that could be an appropriate and safe therapeutic option to resolve a serious health and psychosocial problem: obesity.

**Declaration of interest:** The authors report no declarations of interest. The authors alone are responsible for the content and writing of the paper.

## References

1. Alderman AK, Collins ED, Streu R, Grotting JC, Silkin AL, Neligan P, et al. Benchmark outcomes in plastic surgery: National complication rates for abdominoplasty and breast augmentation. *Plast Reconstr Surg.* 2009;124:2127–2133.
2. Desrosiers AE III, Grant RT, Breitbart AS. Don't try this at home: Liposuction in the kitchen by an unqualified practitioner leads to disastrous complications. *Plast Reconstr Surg.* 2004;113:460–461.
3. Güleç AT. Treatment of cellulite with LPG dermologie. *Int J Dermatol.* 2009;48:265–270.
4. Anderson RR, Farinelli W, Laubach H, Manstein D, Yaroslavsky AN, Gubeli J III, et al. Selective photothermolysis of lipid-rich tissues: a free electron laser study. *Lasers Surg Med.* 2006;38:913–919.
5. Narins RS, Tope WD, Pope K, Ross EV. Overtreatment effects associated with a radiofrequency tissue-tightening device: rare, preventable, and correctable with subcision and autologous fat transfer. *Dermatol Surg.* 2006;32:115–124.
6. Teitelbaum SA, Burns JL, Kubota J, Matsuda H, Otto MJ, Shirakabe Y, et al. Noninvasive body contouring by focused ultrasound: Safety and efficacy of the Contour I device in a multicenter, controlled, clinical study. *Plast Reconstr Surg.* 2007;120:779–789.
7. Manstein D, Laubach H, Watanabe K, Farinelli W, Zurakowski D, Anderson RR. Selective cryolysis: a novel method of non-invasive fat removal. *Lasers Surg Med.* 2008;40:595–604.
8. Rotman H. Cold panniculitis in children: adiponecrosis E frigore of Haxthausen. *Arch Dermatol.* 1996;94:720–721.
9. Zelickson B, Egbert BM, Preciado J, Allison J, Springer K, Rhoades RW, Manstein D. Cryolipolysis for noninvasive fat cell destruction: initial results from a pig model. *Dermatol Surg.* 2009;35:1462–1470.
10. Shek SY, Chan NP, Chan HH. Non-invasive cryolipolysis for body contouring in Chinese—a first commercial experience. *Lasers Surg Med.* 2012;44:125–130.
11. Stevens WG, Pietrzak LK, Spring MA. Broad overview of a clinical and commercial experience with CoolSculpting. *Aesthet Surg J.* 2013;33:835–846.
12. Avram MM, Harry RS. Cryolipolysis for subcutaneous fat layer reduction. *Lasers Surg Med.* 2009;41:703–708.
13. Nelson AA, Wasserman D, Avram MM. Cryolipolysis for reduction of excess adipose tissue. *Semin Cutan Med Surg.* 2009;28:244–249.
14. Klein KB, Zelickson B, Riopelle JG, Okamoto E, Bachelor EP, Harry RS, Preciado JA. Non-invasive cryolipolysis for subcutaneous fat reduction does not affect serum lipid levels or liver function tests. *Lasers Surg Med.* 2009;41:785–790.
15. Coleman SR, Sachdeva K, Egbert BM, Preciado J, Allison J. Clinical efficacy of noninvasive cryolipolysis and its effects on peripheral nerves. *Aesthetic Plast Surg.* 2009;33:482–488.